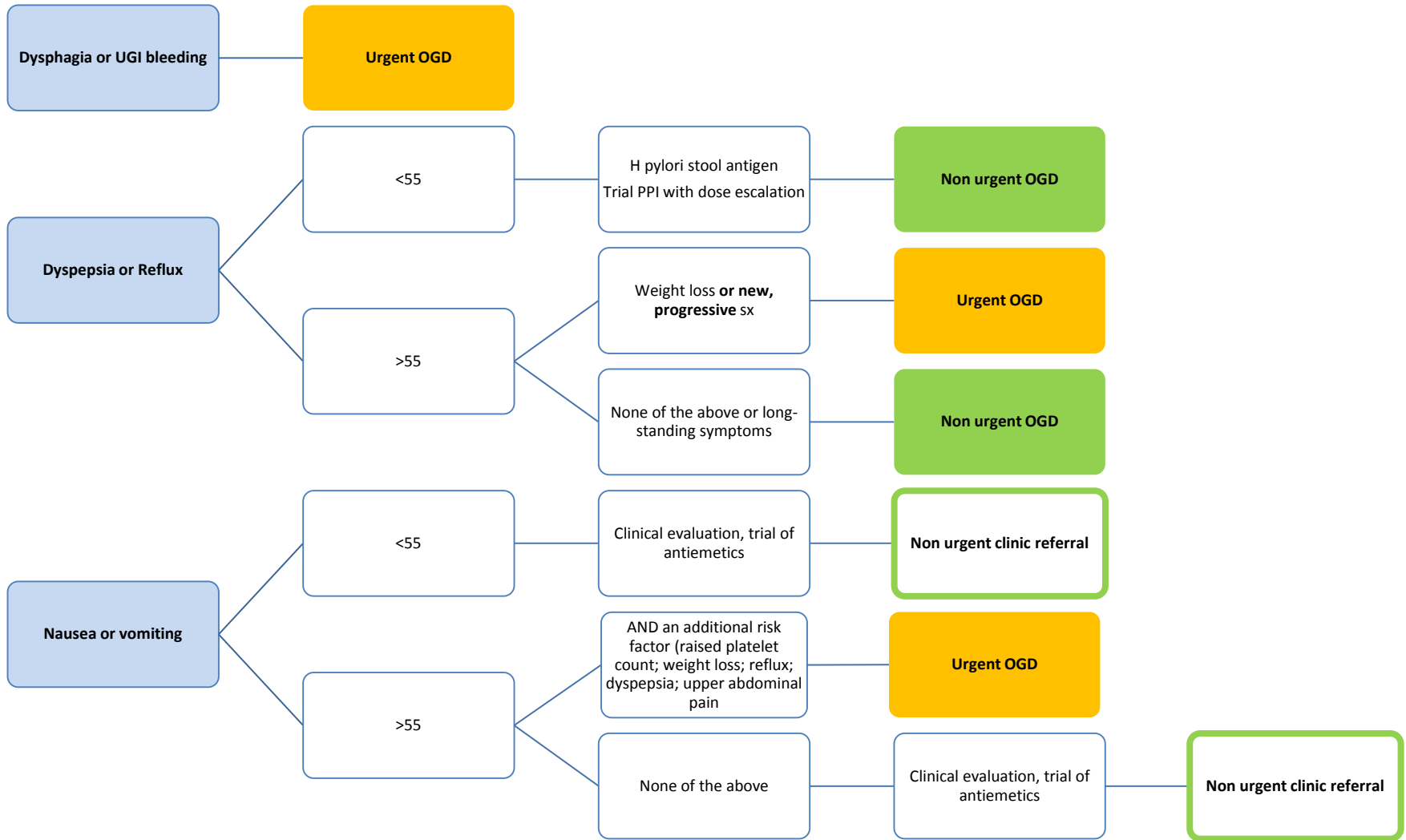


# Upper GI Symptoms



**Age >55 with persisting upper abdominal pain and normal OGD: refer for triple phase pancreatic CT\***

**Age >55 with sustained unexplained weight loss: refer for CT Chest/Abdomen and Pelvis\***

\*ensure recent FBC, U&E, LFT, bone profile either on HUH system or attached to referral